

# Diabetic Retinopathy Classification Using Machine Learning Techniques

S. Regina Lourdhu Suganthi  
Associate Professor  
Department of Computer  
Science  
Mount Carmel College  
Autonomous, Bengaluru

U K Sneha  
Department of Computer  
Science  
Mount Carmel College  
Autonomous, Bengaluru

Shwetha S  
Department of Computer  
Science  
Mount Carmel College  
Autonomous, Bengaluru

## ABSTRACT :

Diabetic Retinopathy is an eye disease which is caused due to long term diabetes. It is one of the major complications of diabetes that affects the blood vessels by causing damage to the light-sensitive tissue. The working age population is largely affected by this disease. At first diabetic retinopathy may cause no symptoms at all. But eventually, it can result in blindness. Ophthalmology is a branch of medicine and surgery that deals with the diagnosis and treatment of eye disorders. The Ophthalmologists use the eye images of the patients to detect and advise preventive care for eye disorders. Using fundus camera the patient's eye image is acquired as these Eye images are the primary data source for the classification. The images in its original form may not reveal the necessary features that are used for the purpose of classification. Thus, to apply machine learning algorithms, various attributes from the eye image are extracted using the domain knowledge to reveal different characteristics of the disease pattern. Automatic classification using machine learning techniques are generally rigid. Deep learning technique has been used for automatic classification and prediction with high accuracy. The pre-processed eye image data set is used to train the classifier for binary classification to infer the patient's eye as an infected eye or a normal eye. The model has been evaluated using various measures namely, Precision, Recall, and F-Score. The severity of the disease is measured and classified into different categories using machine learning algorithms.

**Keywords :** *Decision Tree classifier, Random Forest, Support Vector Machine, Deep Learning, CNN, Diabetic Retinopathy, Machine Learning, ROI*

## 1. INTRODUCTION

Diabetes mellitus is a metabolic disorder. Chronic complications of this disorder include cardiovascular disease, chronic renal failure and diabetic retinopathy. The objective of this work is to classify the eye image of a patient as normal eye or an infected eye in the context of

diabetic retinopathy. The fundus of the eye is the interior surface of the eye opposite to the lens and includes the retina, optic disk, macula, fovea and posterior pole. The Diabetic Retinopathy (DR) infected eye is characterized by the presence of the following lesions. *Micro aneurysms* : These are localized capillary dilations which are usually round in shape and often appear as clusters of small red dots. These are the early signs of DR and do not affect the vision. *Exudates* : Hard exudates are distinct yellow white intra-retinal deposits which can vary from small specks to large patches. The soft exudates have unclear boundaries called cotton wool spots and are greyish white patches. When exudates occur in the macula, the vision loss occurs. *Hemorrhages* : These lie deep within the retina and reflect leakage of veins and capillaries. If the amount of bleeding is small, only a few dark spots (floaters) are seen whereas in severe cases blood can fill the vitreous cavity and block the vision.

Several real life problems involve the classification of data into categories or classes. Given a dataset containing the data whose classes are known, Machine Learning algorithms could be employed for the induction of a classifier and to predict the class of a new data from the same domain at ease. The prominent features of the eye images that have been selected for learning and classification are :

- ❖ Optic Disc diameter
- ❖ Lesions
  - Hemorrhages
  - Exudates
- ❖ Distance of nearest lesion from fovea

Deep learning is part of a broader family of machine learning methods based on learning data representations. Convolutional neural network (CNN) is a class of deep, feed-forward artificial neural networks that has successfully been applied to analyzing visual imagery. CNNs use relatively minimal pre-processing compared to other image classification algorithms. The network learns the filters automatically unlike the traditional algorithms where the features are generally hand-engineered. This

independence from prior knowledge and human effort in feature design is a major advantage of CNN. In this work both hand-engineered features and automatic feature extraction are deployed.

The paper is organized as follows : Section 2 introduces the literature review on feature extraction and classification techniques proposed by various Researchers. Section 3 presents the proposed framework and methodology used for DR eye image classification. Section 4 gives the experimental results and Section 5 concludes with scope of the work combined with the challenges.

## 2. LITERATURE REVIEW

Human eye is an important part of the body. Disease like diabetic retinopathy can cause irreversible damage to the vision if it is not detected and treated at the early stages. Retinal images known as fundus images have red tint due to rich blood supply and they contain optical disk, and macula. These are important for diagnosis. A method for automatic detection of the macula using multilevel thresholding has been discussed by the Researchers[1].

In the initial stage of DR, the damages are seen in small retinal blood vessels. When it advances, they become abnormal and bleed. The leak produces sediments composed of lipid byproducts called exudates[2]. Several algorithms based on filtering, contrast adjustment, morphological processing have been used to detect exudates. Automatic extraction of exudates using differential morphological profile, circular Hough transform and Gabor filtering and thresholding have been proposed. [3]

The identification of haemorrhages is one of the essential element in the early analysis of DR .Recognition of haemorrhages in DR is a main diagnostic standard to find out the severity of the disease .Hemorrhages are caused when the retinal blood vessels bleed if the amount of bleeding is small you might notice only few dark spots or floaters. And in severe cases blood can fill the vitreous cavity and block our vision. Different techniques are implemented for extraction of haemorrhages. Hybrid method [4] which involves several steps like template matching , filtering ,thresholding ,false positive reduction and detection of haemorrhages . Automatic extraction of haemorrhages using digital image processing techniques like green channel extraction ,histogram equalization ,image enhancement, intensity transformation ,thresholding and morphological opening have been proposed[5].

The optic disc is a key anatomical structure in retinal images. The positions and radius of optic disc can be used as the references for approximating fovea detection. Ability to detect optic disc in retinal image plays a important role in automated screening system .Local feature spectrum analysis (LFSA) [6] technique has been proposed to automatically detect optic disc .which involves several steps like local feature extraction ,dictionary selection, local feature spectrum and classification (SVM & k- nearest 2neighbor) .The advantage of this method is it does not require vessel segmentation technique.

Supervised and unsupervised learning techniques are the basic classification methods. Classification accuracy is based on the choice of feature in the data set. Decision tree classifiers and Neural Network based classifiers present better classification accuracy for certain problem domains on the other hand combination of more than one classifier may yield better performance [7][8]. Complex problems can be solved by training the model using features that are automatically extracted at various levels or by using hand engineered techniques. Machine Learning systems could be trained until the system has achieved good performance. It is the science of getting computers to act without being explicitly programmed. [9].

## 3. FRAMEWORK

The process flow sequence of primary processes that form the basis for classification is shown in figure 1. Fundus image data set is collected from various sources and is used for classification. Deep learning model of a simple classifier with Keras, a neural network API written in python, has been used for learning. The model trains a small network from baseline.

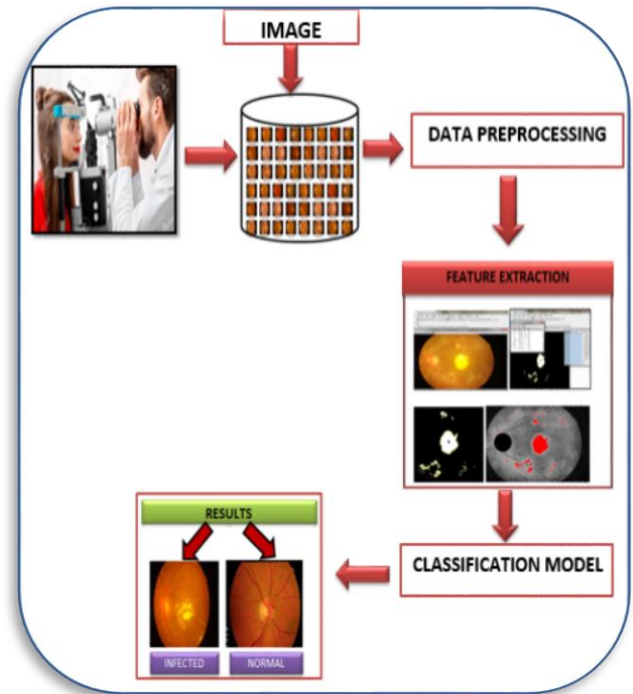


Figure 1 : Process Flow

The fundus image of a normal retina and an infected retina are shown in figure 2. Fundus image of infected eye with different lesion is shown in figure 3.

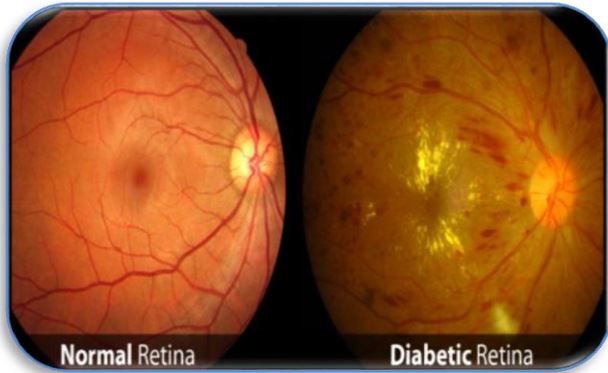


Figure 2 : Fundus Eye image

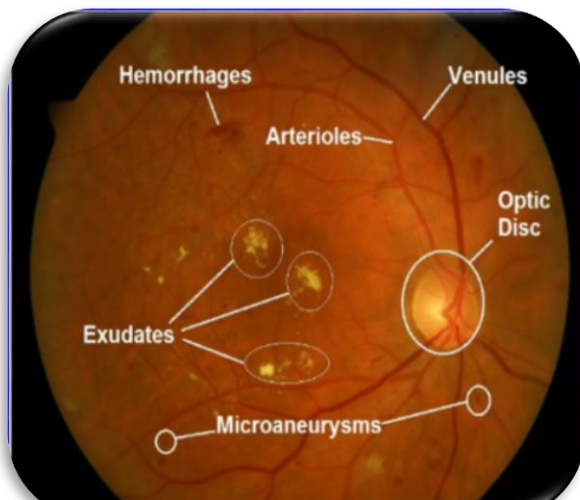


Figure 3: Infected Fundus Eye image with lesions

### 3.1 Data Pre-processing

The Eye image dataset has been resized to improve the processing speed. The dataset is subjected to binary classification using deep learning technique in order to be classified as an infected eye or a normal eye. In the next stage, significant attributes that are the general cause for Diabetic Retinopathy were selected. The attributes chosen are :

- ❖ Optic Disc diameter
- ❖ Lesions
  - Hemorrhages
  - Exudates
- ❖ Distance of nearest lesion from fovea

### 3.2 Feature Extraction

To extract lesions from the image, Open ImageJ software tool has been used. After converting the image into gray scale image and enhancing the contrast of the image, the lesions are extracted by

identifying the region of interest (ROI) with an appropriate threshold as shown in figure 4. The digimiser software is used to measure and compute the distance of nearest lesion from fovea as displayed in figure 5.

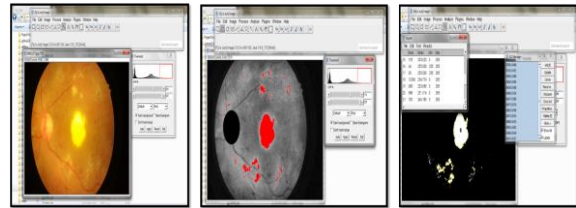


Figure 4 : Exudates extraction

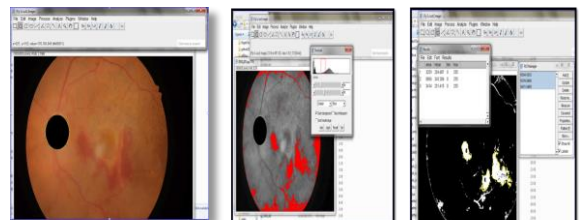


Figure 5 : Hemorrhage extraction

### 3.3 Classification Model

The classification is done in two phases. In the first phase, the dataset is pre-organized into groups with class labels in the ratio 70:30. The 70% of the images are used for training the classification model to automatically learn the features from the images through deep neural nets. The 30% of the images from the fundus eye image dataset is used for model validation. The images are then loaded respectively into the model and setting the classification mode to binary along with respective class labels. The learning model is fit using functions imported from Keras library with sub sampling techniques, convolution filters, optimizers and activation functions. The model is then validated. To improve the model accuracy, the image augmentation techniques, namely shear and flip operations are applied on the fundus images and then again loaded into training and validation sets.

In the second phase, in order to measure the severity of the disease, classifiers namely, Decision Tree Classifier, Support Vector machine and Random Forest have been used. The features extracted to identify and scale the severity of the disease, along with the thresholds used for categorizing the classes are listed in Table 1. The decision tree constructed for generating class labels is shown in figure 6.

Sl.No	Feature	Threshold
1	Optic disc diameter in mm	1.8 mm
2	Nearest lesion from fovea	2 * Median
3	Exudates	Median
4	Hemorrhages	Median / 4

Table 1

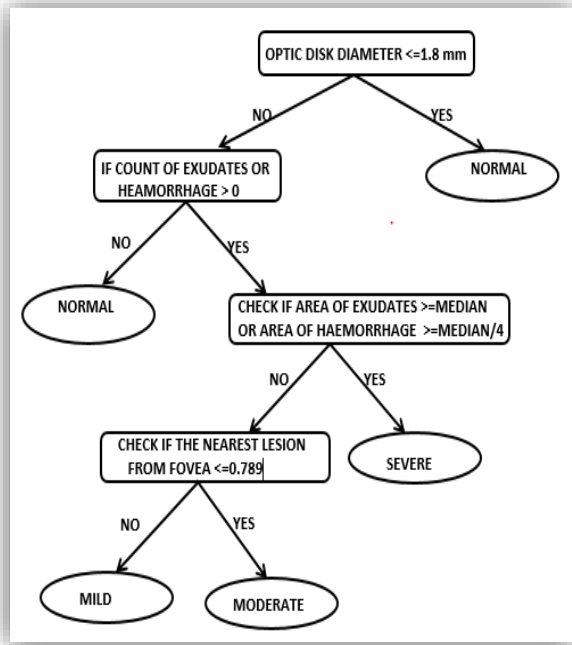


Figure 6 : Decision Tree

The features chosen for training and validation are : optic disc diameter in mm, count of exudates, count of hemorrhages, area of exudates, area of hemorrhage, nearest lesion from fovea in mm and the class labels namely normal, mild, moderate and severe. The results of the three classifiers namely Decision tree classifier, SVM and Random Forest, have been analyzed using the confusion matrix and are compared.

#### 4. EXPERIMENTAL RESULTS

A sample set of totally 664 eye images were downloaded from Indian Diabetic Retinopathy Image Dataset (IDRID) and few other sources. This image set has been divided in the ratio 70:30 for Training and Validation purpose. This resulted in the training data set with 465 images and Validation data set with 199 images. The training set had 413 DR infected Eye images and 52 normal eye images whereas the validation set had 103 DR infected images and 96 normal eye images.

The deep learning technique has been implemented in Python Language with Tensorflow framework. Multiple layered model has been designed for performing convolution and feature extraction. Rectified Linear Unit (ReLU) activation function is used to define the output of internal layers. As the objective in stage 1 is binary classification, the Sigmoid activation function has been used in the output layer. MaxPooling2D with two strides has been used to reduce the dimensionality of the data with binning to help avoid model overfitting. The model loss, accuracy and mean squared error with 15 Epochs are shown below :

```
In [10]: print ("Loss, Accuracy, Mean Squared Error")
model.evaluate_generator(validation_generator, validation_samples)
```

Loss, Accuracy, Mean Squared Error

```
Out[10]: [0.26714849085641257, 0.9798030765542356, 0.022484759799034321]
```

The graphs of the above values are shown in figure 7, figure 8 & figure 9.

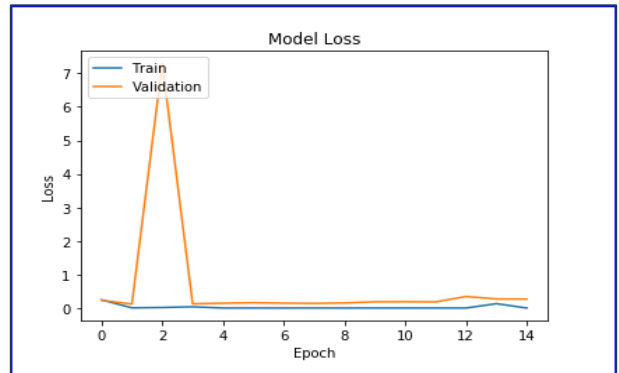


Figure 7 : Model Loss

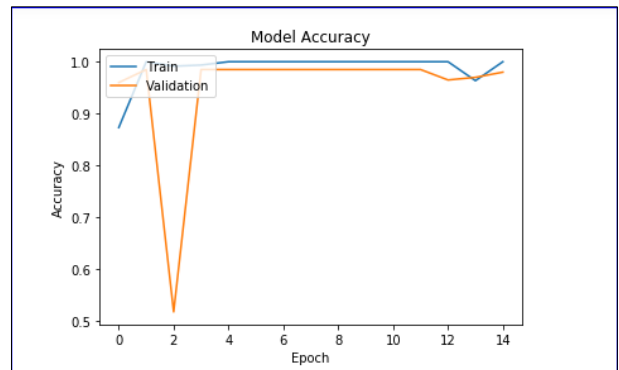


Figure 8 : Model Accuracy

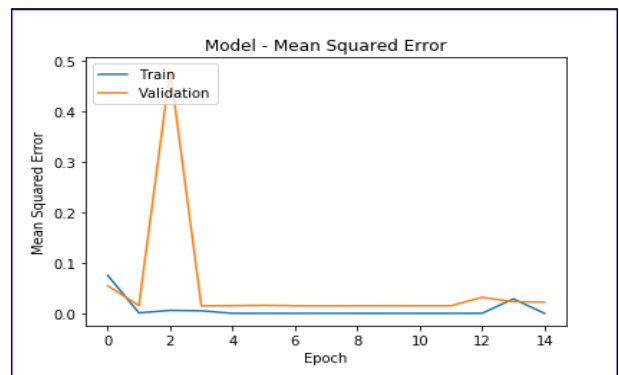


Figure 9 : Mean Squared Error

The images were subjected to augmentation and the model was compiled once again. The results below reveal that the accuracy of the model has been improved after augmentation.

```
In [13]: print ("Loss, Accuracy, Mean Squared Error")
         model.evaluate_generator(validation_generator, validation_samples)

Loss, Accuracy, Mean Squared Error

Out[13]: [0.046438615138693497, 0.98989898798742681, 0.010496621741042978]
```

The experimental results of various classifiers for identifying the severity ( Mild, Moderate, Severe ) of the DR infected eye are listed below. The features used in the classifiers for learning are Optic Disc Diameter, Count of Exudates, Count of Hemorrhage, Area of Exudates, Area of Hemorrhage, Nearest Lesion from Fovea. A sample labeled data set with its features is shown in Table 2. The first column and the last column in Table 2 are the Image Id and Class labels respectively.

image_100	1.8230	0	0	0	0	0	NORMAL
image_104	1.8119	0	0	0	0	0	NORMAL
IDRiD_003	4.262	42	0	8690	0	0.839	SEVERE
IDRiD_007	3.257	32	0	3414	0	0.874	MILD
IDRiD_009	3.603	51	0	5016	0	0.31	MODERATE
IDRiD_0010	4.88	50	0	41765	0	0.173	SEVERE
IDRiD_0020	4.054	50	0	4086	0	0.383	MODERATE
IDRiD_0025	3.292	70	0	13283	0	0.485	SEVERE
IDRiD_0032	3.673	36	0	2771	0	2.484	MILD
IDRiD_0048	3.499	39	0	2505	0	1.315	MILD
IDRiD_0049	3.188	37	0	4931	0	1.26	MILD
IDRiD_0015	3.43	14	0	93645	0	0.5	SEVERE
IDRiD_0017	3.985	20	0	10355	0	1.01	SEVERE
IDRiD_0022	2.83	28	0	28006	0	0.278	SEVERE
IDRiD_0024	3.569	76	0	8918	0	0.286	SEVERE
IDRiD_0029	3.222	33	0	4400	0	0.737	MODERATE
IDRiD_0030	3.361	33	0	7064	0	0.271	SEVERE
IDRiD_0033	3.361	27	0	12874	0	2.873	SEVERE
IDRiD_0035	3.534	62	0	11359	0	0.222	SEVERE
IDRiD_0042	2.91	23	0	9860	0	0.625	SEVERE
IDRiD_0050	3.777	53	0	1676	0	1.165	MILD
IDRiD_0053	3.604	42	0	2959	0	0.877	MILD
IDRiD_0055	3.465	28	0	5066	0	0.279	MODERATE
IDRiD_066	2	51	0	5384	0	0.166	SEVERE
IDRiD_009	2.081	39	0	2551	0	0.356	MODERATE
IDRiD_0015	1.5	29	0	6489	0	0.233	NORMAL
IDRiD_017	2.081	41	0	10741	0	0.922	SEVERE

Table 2 : Sample Labeled Data Set for Machine Learning

The machine learning algorithms applied for learning and the corresponding learning model accuracy are shown in Table 3. The total number of eye images used for learning is 199 fundus images. Thus the confusion matrix obtained for the three classifiers on the validation data set is given below in Table 4, Table 5 and Table 6.

Sl.No	Classifier	Model Accuracy
1.	Decision Tree	98.305
2.	SVM	86.441
3.	Random Forest	96.610

Table 3 : Model accuracy

## 5. CONCLUSION AND SCOPE

The results in the confusion matrix reveal that the performance of Decision Tree classifier is superior to SVM classifier and Random Forest technique. Additional features though may not be significant could also be identified and added to the feature set to improve the prediction results. The thresholds used for categorizing the severity of the disease could be optimized. The images could directly be subjected to deep learning model to automatically predict the severity of the disease with better accuracy. The size of the data set could also be increased in order to minimize the model error and improve accuracy.

## 6. REFERENCES

- [1] Jiri Minar, Kamil Riha, Ales Krupka, Hejun Tong, "Automatic detection of the macula in retinal fundus images using multilevel thresholding"
- [2] A. Biran, P. Sobhe Bidari, K Raahemifar, "Automatic method for Exudates and Hemorrhages detection from Fundus Retinal Images", International Journal of Computer and Information engineering, Vol. 10, No.9, 2016.
- [3] Wuttichai Luangruangrong, Pusit Kulkasem, Suwanna Rasmeequan, Annupan Rodtook, Krisana Chinnasarn, "Automatic exudates detection in retinal images using efficient integrated approaches", Signal and Information Processing Association Annual Summit and Conference (APSIPA), 2014. Pgs 1-5.
- [4] International Journal of Computer Applications (0975 – 8887) Volume 107 – No 12, December 2014

[5] Detection of Haemorrhage from Retinal Images Using Digital Image Processing Techniques. 2017 IJEDR | Volume 5, Issue 4 | ISSN: 2321-9939

[6] Automatic Optic Disc Detection in Color Retinal Images by Local Feature Spectrum Analysis. Hindawi ,Computational and Mathematical Methods in Medicine Volume 2018, Article ID 1942582, 12 pages

[7] S Regina Lourdu Suganthi, M Hanumanthappa, S Kavitha, "Event Image Classification using Deep Learning", IEEE, International Conference on Soft-computing and Network Security (ICSNS), 2018

[8] Ioffe, Sergey, and Christian Szegedy. "Batch normalization: Accelerating deep network training by reducing internal covariate shift ." arXiv preprint arXiv:1502.03167 (2015).

[9] Simonyan, K. and Zisserman, A, "Very deep convolutional networks for large-scale image recognition", Proceedings of International Conference on Learning Representations. <http://arxiv.org/abs/1409.1556> (2014).